

Urodynamics tracing review

Anne Cameron MD FRCSC URPS

1

How to read UDS the easy way

- 4Cs 2 Ss and the pressure flow:
- Capacity, Compliance, Contractions, Coughs
- Sensation, Sphincter function
- PdetQmax, Qmax, Straining

2

There are only 6 UDS diagnoses so don't overcomplicate:

- SUI
 - DO
 - BOO anatomic
 - BOO functional
 - DU/atonic
 - poor compliance
- Also the clinical picture usually excludes HALF of these

3

Case #1

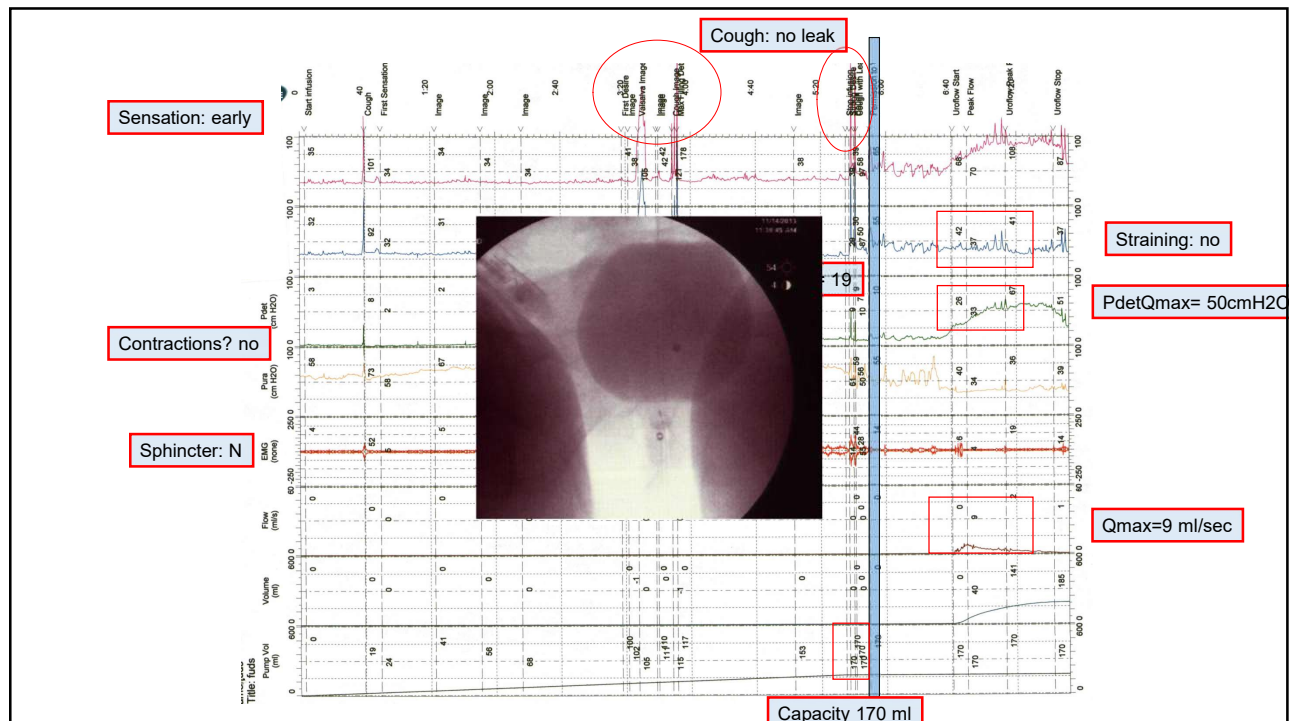
- 55 y/o healthy woman 6 months post synthetic MUS
- Had SUI before sling and now has unpredictable incontinence and new urgency
- No UTIs, PVR=0, operative report reviewed and no complications

4

What is the primary urodynamic question? IS this...

- OAB
- SUI vs DO
- Obstruction vs not
- Poor compliance
- Underactive bladder

5

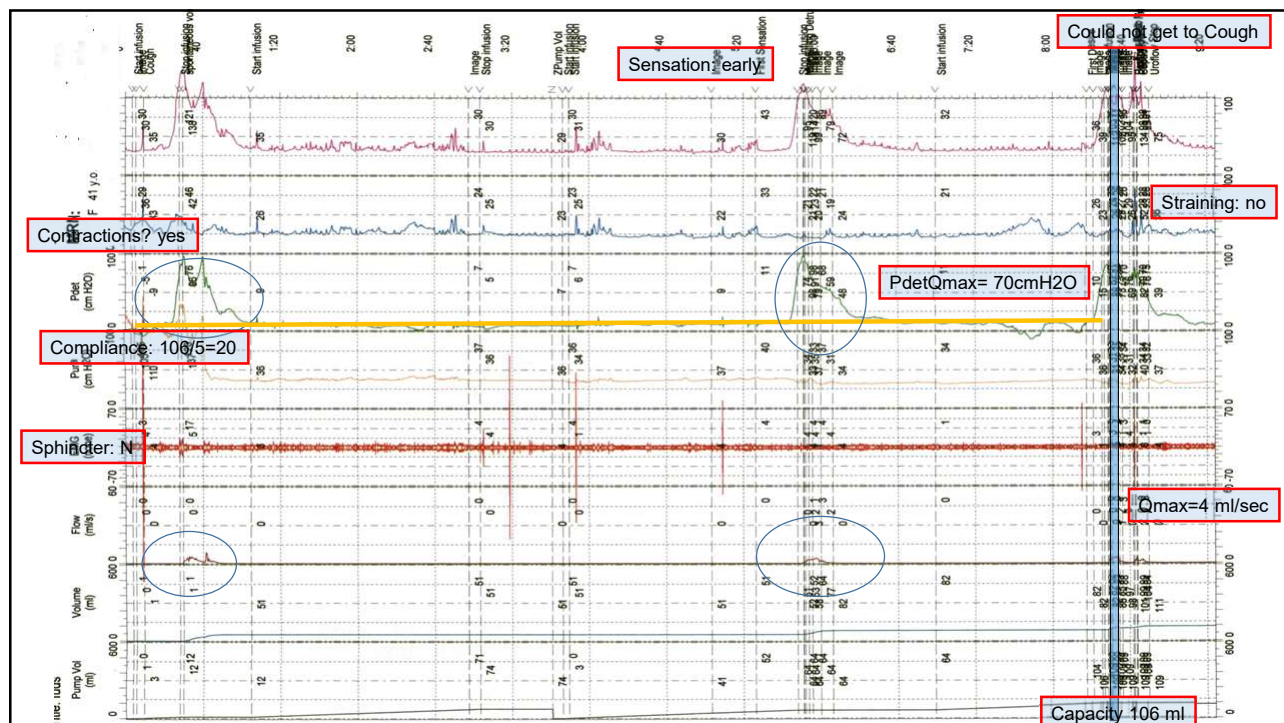


6

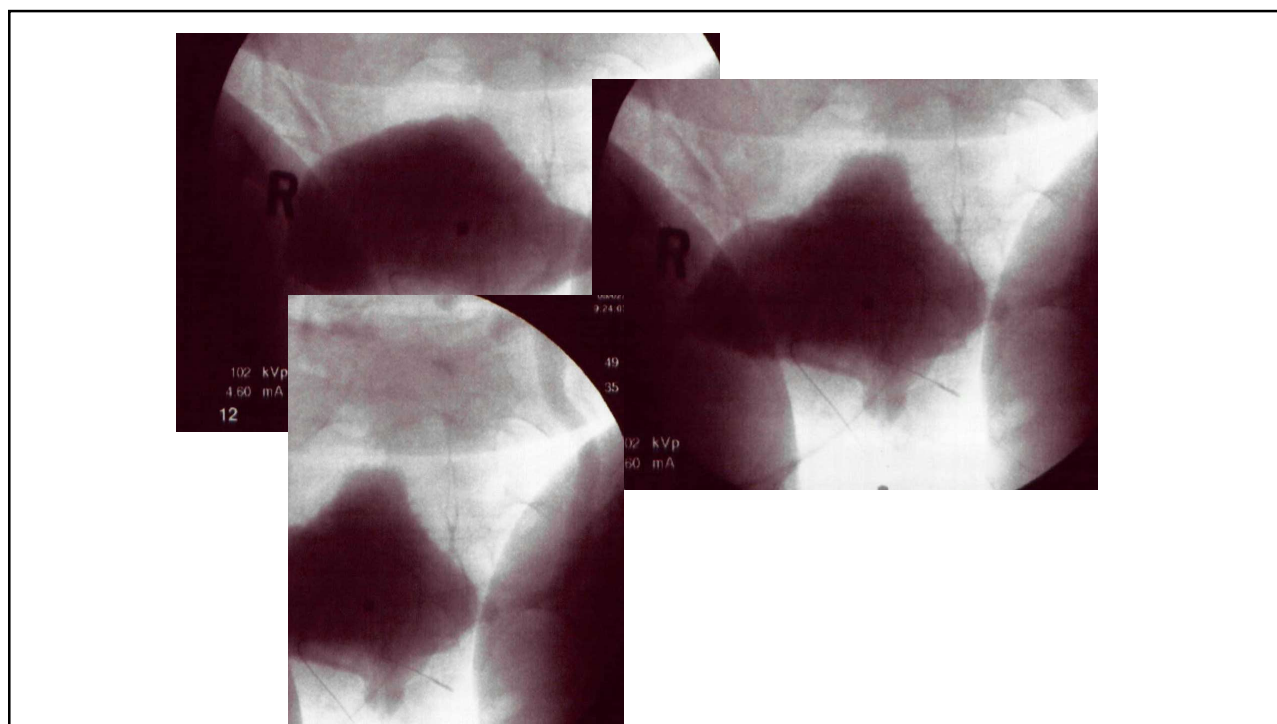
Case 2- PVR of 200

- 41-year-old G2P2 woman who has secondary progressive multiple sclerosis
- 1year history of leaking with urge but also hesitancy and difficulty emptying her bladder
- Frequency three to four times per hour+ slow stream and nocturia x3
- No: UTI, blood or stones
- Long history of SUI mild since baby #2
- Physical exam: normal pelvic support, urethra hypermobile and no volitional Kegels 0/5

7



8

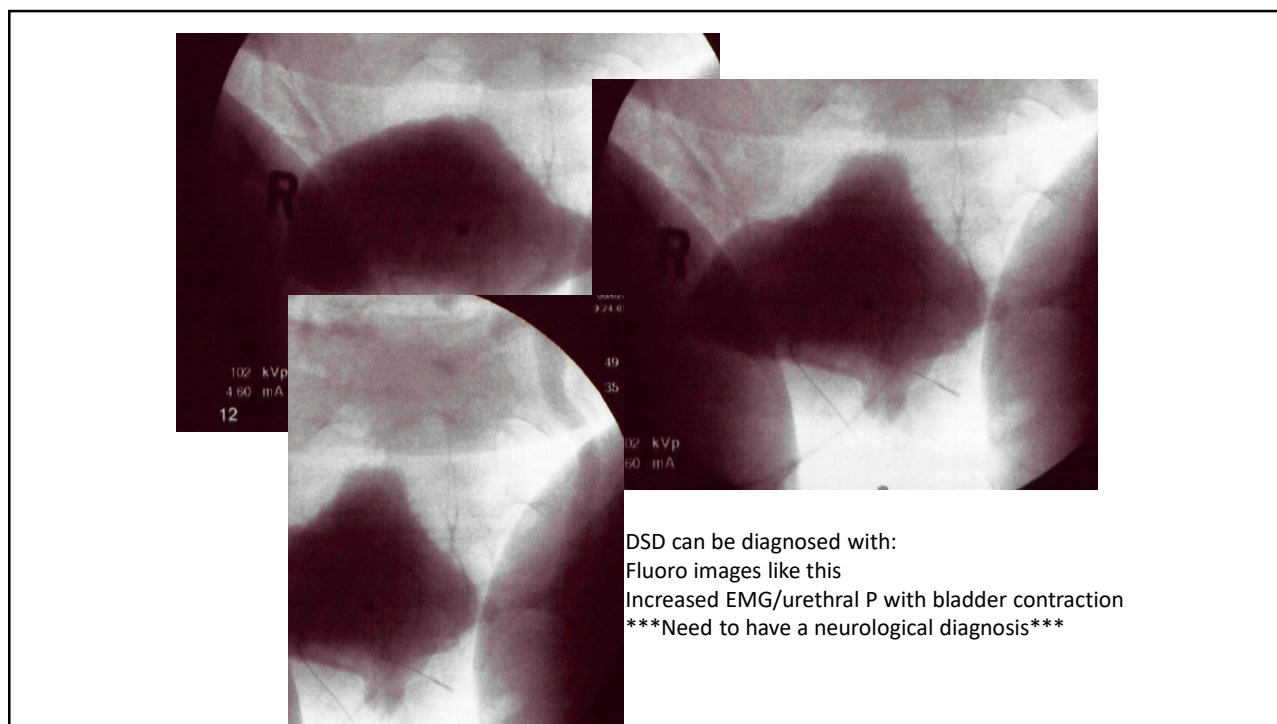


9

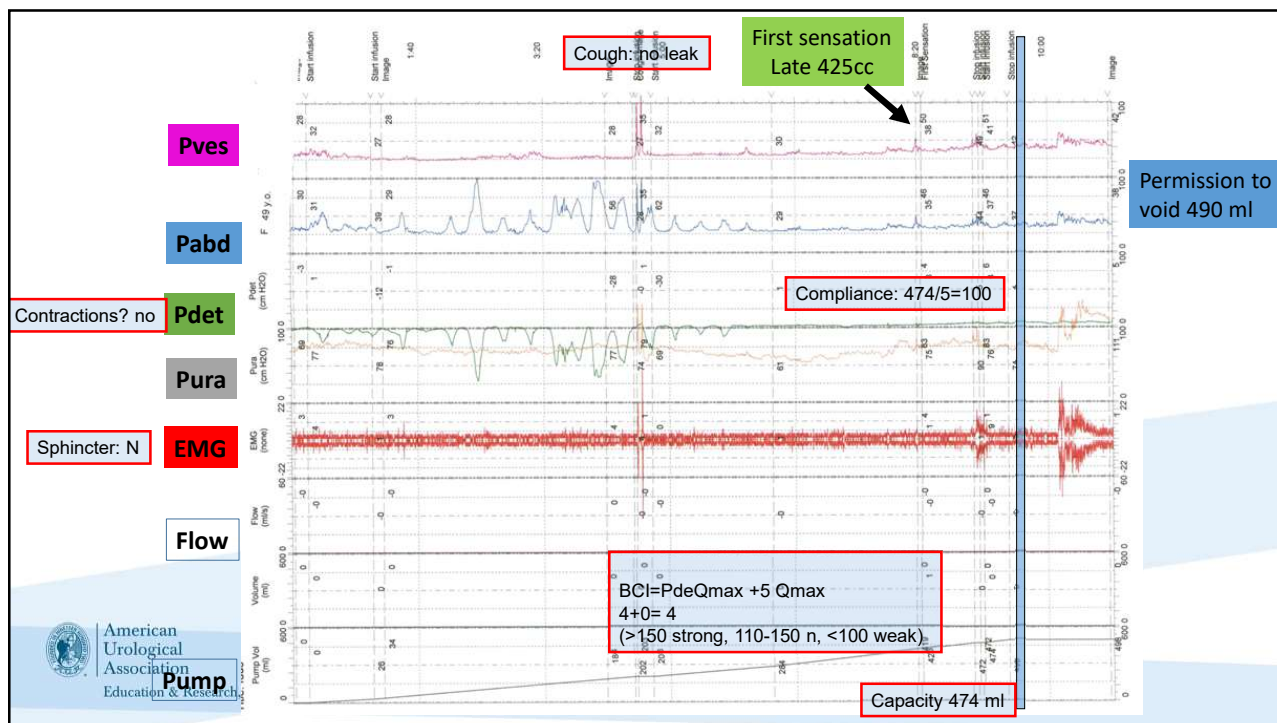
What is her diagnosis?

- OAB
- DO
- VUR
- DSD
- DSD+DO
- **DSD+DO+VUR**

10



11

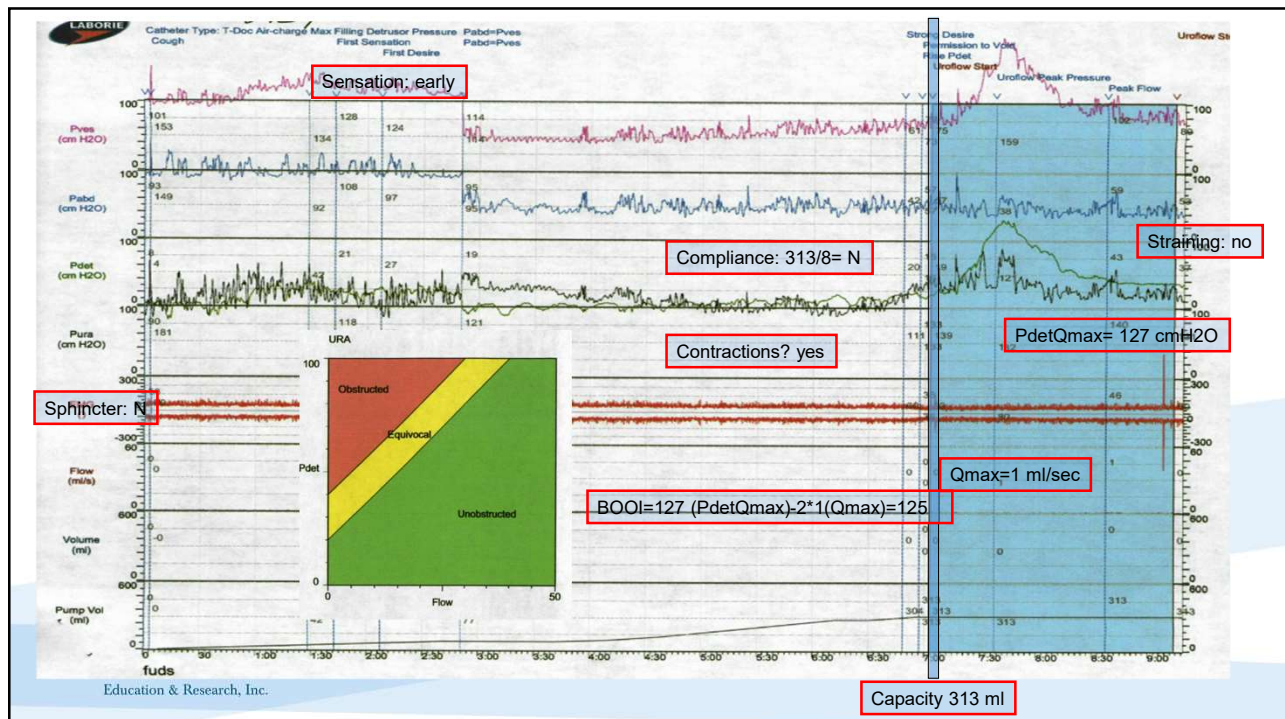


12

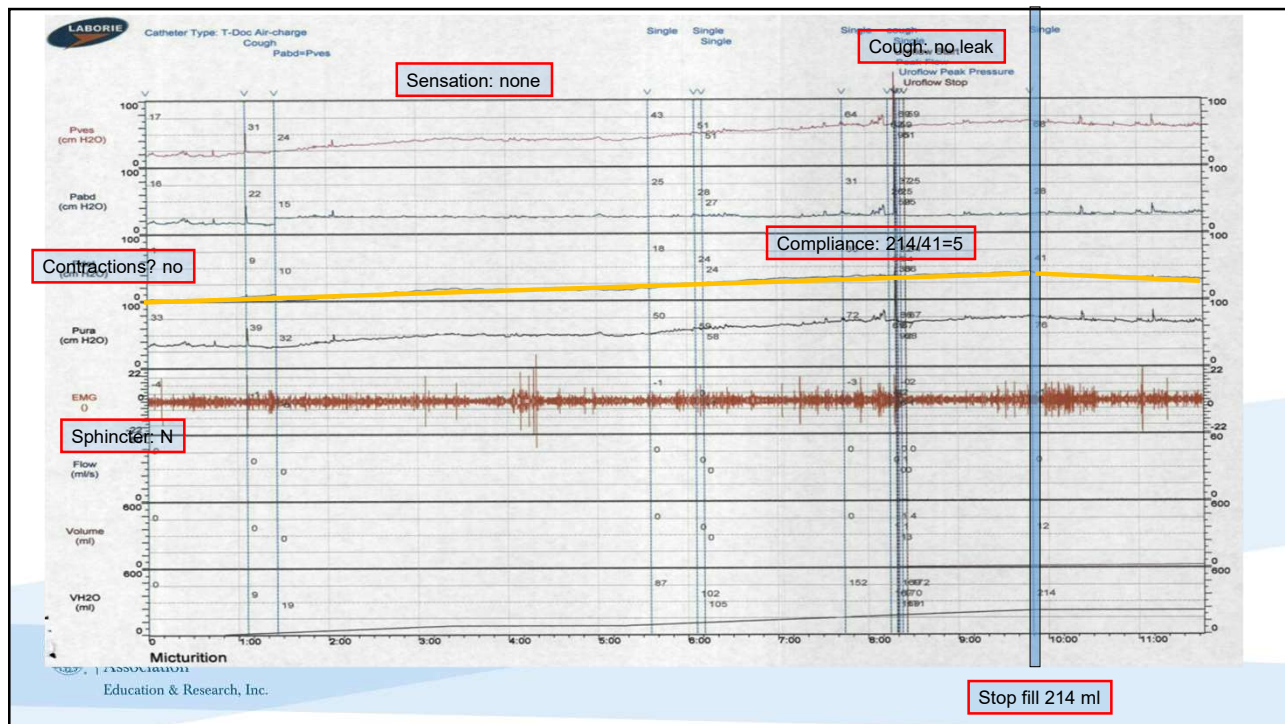
Why is this patient in retention?

- Atonic bladder
- Urethral disease
- Bladder outflow obstruction
- Fowler's syndrome
- DSD

13



14

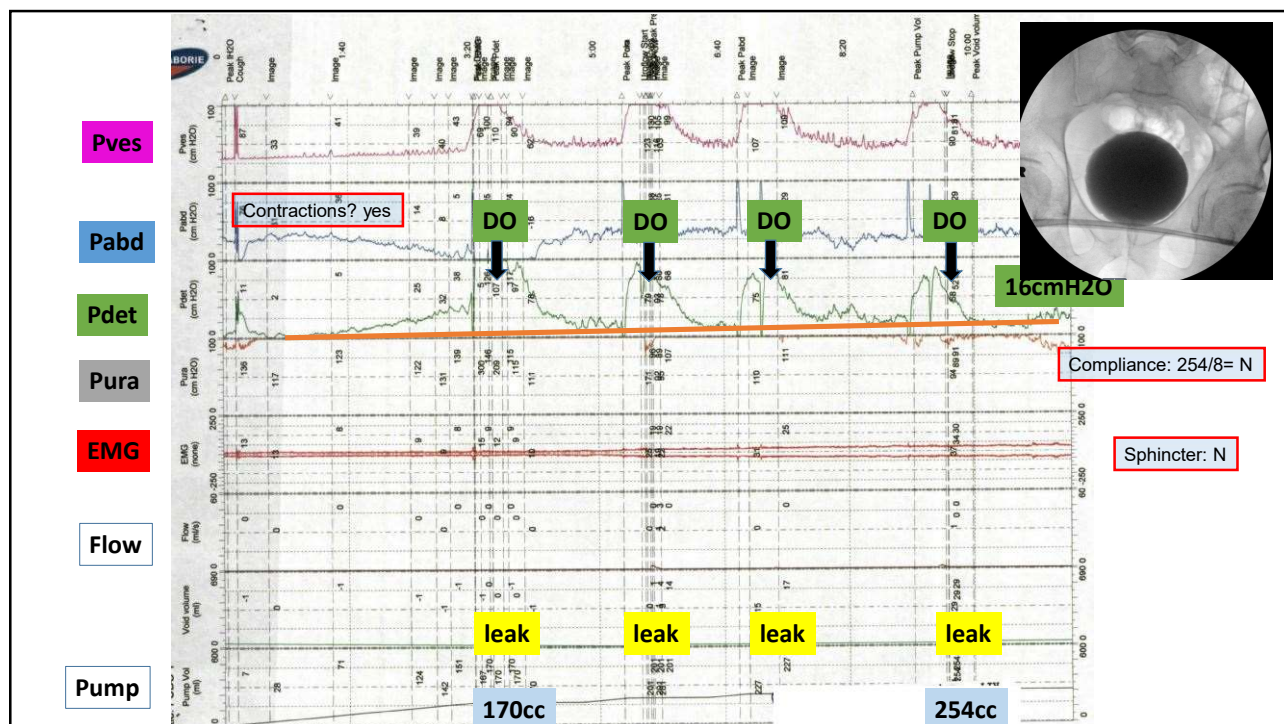


15

54 y/u with transverse myelitis

- Paraplegia
- In retention since event
- CIC 5 x a day
- Leaking between caths despite oxybutynin 15 mg and then mirabegron 50

16

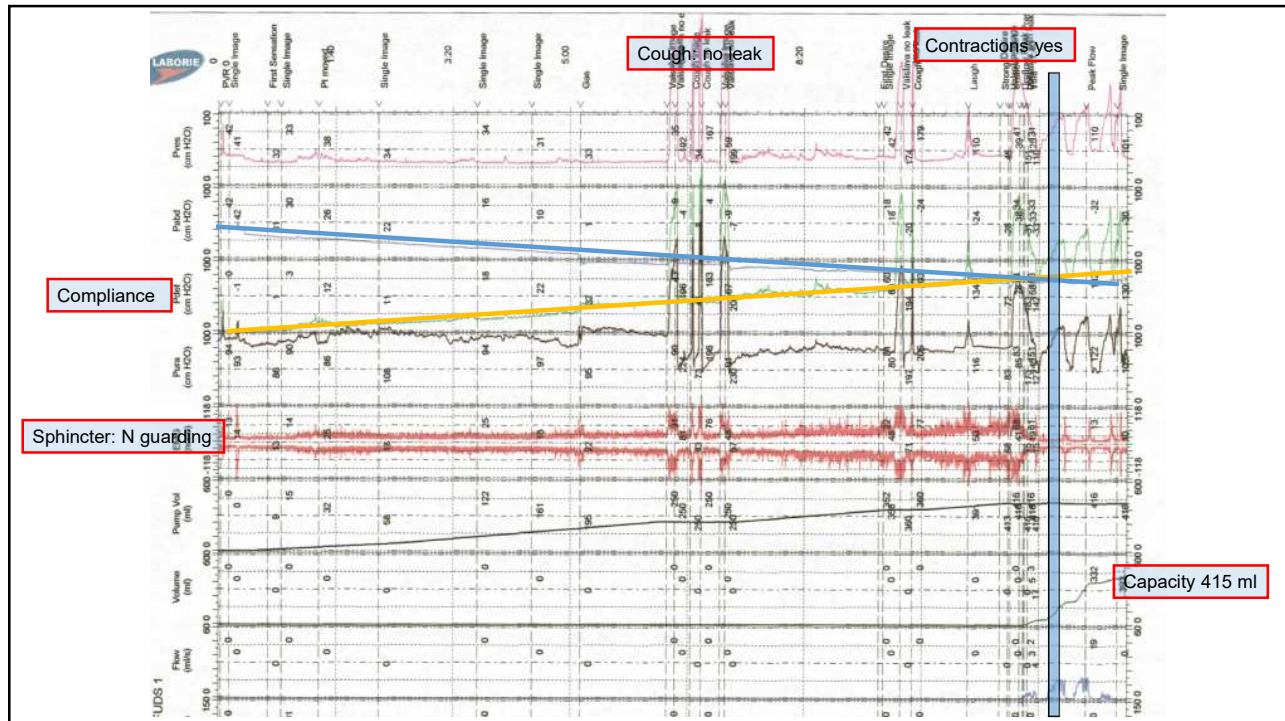


17

Case 5

- 50 y/o G3P3 female with mixed incontinence symptoms
- DMII
- dyspareunia

18

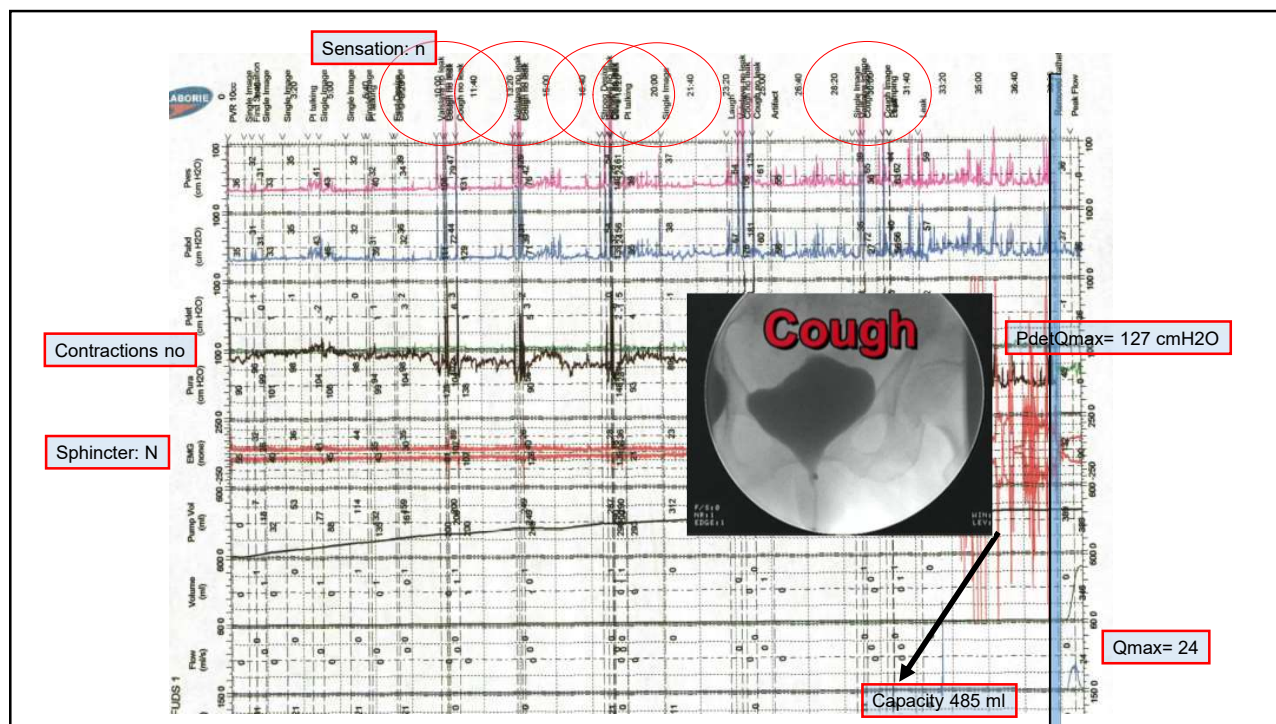


19

Case #6

- 45 year old G3P3 healthy karate instructor with incontinence
- SUI>>UUI
- Full bladder stress test in clinic negative

20

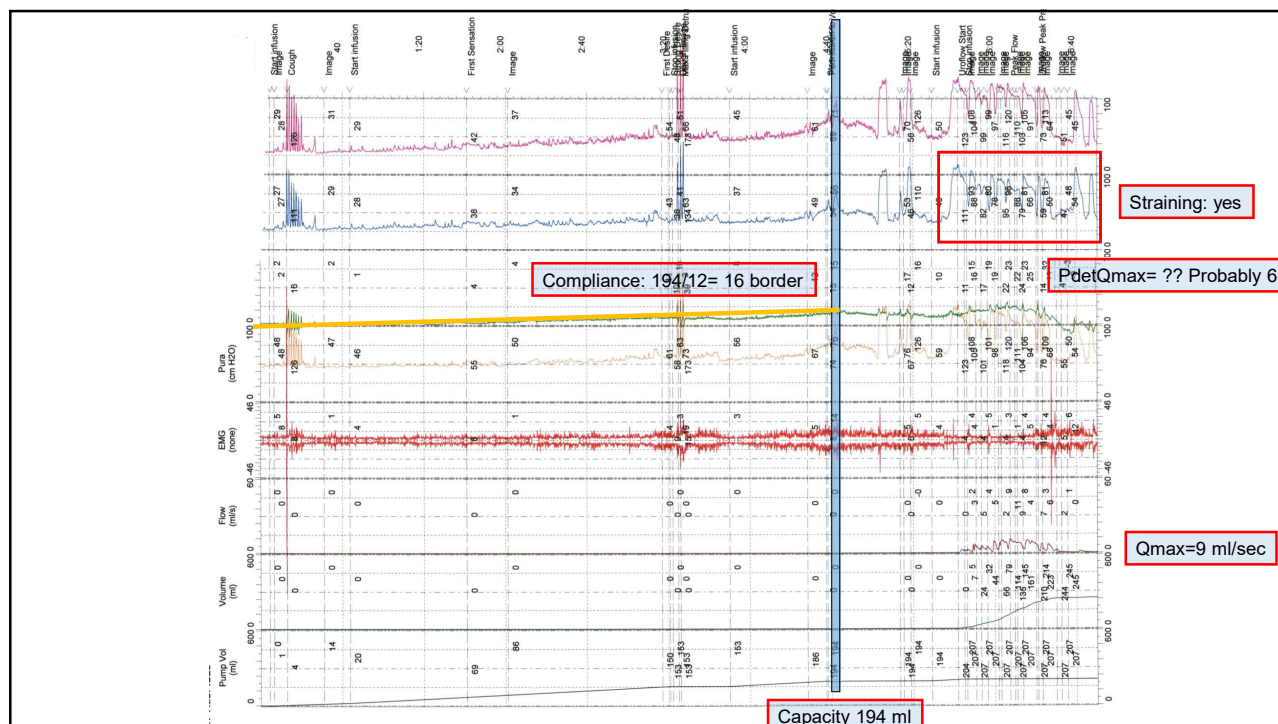


21

Case 7

- 84 y/o woman with incontinence and straining to void
- XRT for cervical cancer 5 years ago
- failed oral agents

22



23

What are the diagnosis?

- Poor bladder compliance
- SUI
- Detrusor underactivity
- Straining to void

24

There are only 6 UDS diagnoses so don't overcomplicate:

- SUI
 - DO
 - BOO anatomic
 - BOO functional
 - DU/atonic
 - poor compliance
- Also the clinical picture usually excludes HALF of these

25

Good Luck!!

Anne Cameron- annepell@med.umich.edu

26